

21st Mid-Atlantic Burn Conference



November 15 - 16, 1998
Baltimore, MD

**Dynamic Cone Mouth Splinting:
Adjunct to Present Scar
Managemet Techniques**

*Barbara Knothe, MOT, OTR/L, CHT,
& Frederick A. DeClement, MD, FACS*

Dynamic Cone Mouth Splinting: Adjunct to Present Scar Management Techniques.¹

Barbara Knothe, MOT, OTR/L, CHT, & Frederick A. DeClement, MD, FACS

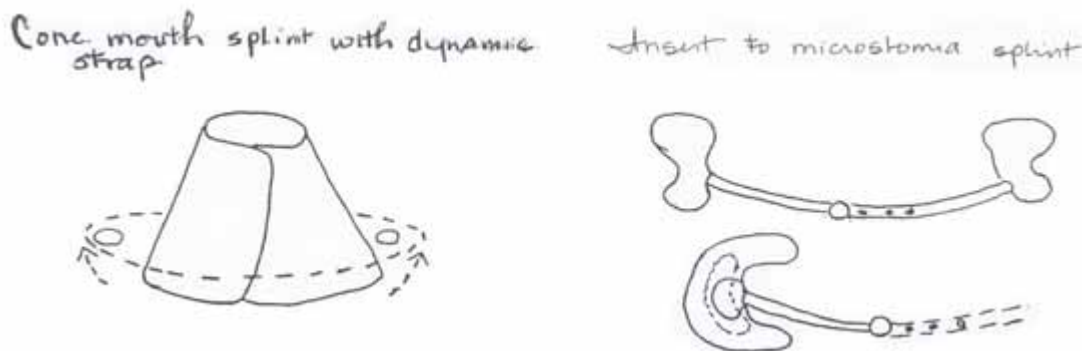
ST. AGNESS BURN CENTER, PHILADELPHIA, PENNSYLVANIA

Oral commissure burns often develop significant skin tightness which contributes to functional impairments and cosmetic deformities. Available microstomia splints provide management, in addition to exercise, scar massage and ROM techniques which can reduce skin tightness and potential contracture formation. However, these devices are not without limitation – most notably cost and only available in standard sizes that don't often match the patient needs.

Low cost splinting techniques can enhance vertical and horizontal stretch in effectively managing this type of scar formation alone or in conjunction with off the shelf devices. Of particular note, a new low temperature silicone bonded thermoplastic material (Silon- LTS[®]) has been developed which can aid in the utilization of making these thermoplastic mouth devices more suitable for managing these difficult oral contractures.

Two prototypes for managing microstomia will be presented a diagram of forming and application procedures will be provided (Diagram 1). A silicone lined cone mouth splint with dynamic straps adds to unique components – a moldable silicone lined material that enhances contact for increasing graduated stretch and an elastic strap allows for ease of application and adds a dynamic stretch component. The low temperature silicone bonded inserts can add more vertical stretch to commercial microstomia splints (such as the MPA) further adding increased stretch and also providing a more comfortable and tolerable stretch with this soft, silicone lining. These inserts may be removable or fixed permanently into the device. These two splinting techniques can dramatically improve functional and cosmetic results decreasing the need for other reconstructive surgery.

Diagram 1 Mouth Splinting Prototypes for Microstomia



¹ [abstract] In: Proceedings of the 21st Annual Mid-Atlantic Region Burn Conference 1998; Nov 15-16; Baltimore, MD, p.29.