



SMA :: Southern Medical Association
Professional Development Planner
 Vol. 3, Issue 12, September 2006

The 19th Annual Southern Region
BURN CONFERENCE
 NOVEMBER 3 - 5, 2006

Washington Duke Inn and Golf Club • Durham, North Carolina

Hosted by North Carolina Jaycee Burn Center



Southern Medical Association Medallion Level
 CME and Lifelong Professional Development



This program is endorsed by the
 American Burn Association (ABA) and
 is held in cooperation with the Southern
 Region Burn Centers of the American
 Burn Association

PRE-CONFERENCE ACTIVITIES

- Advanced Burn Life Support Courses
- Advanced Hazmat Life Support Courses
- Rehabilitation Workshop: Burn S.C.A.R.S.
 (Science Considerations & Rehab Strategies)
- Child Abuse by Burning: Pattern
 Recognition and Unit Responsibilities

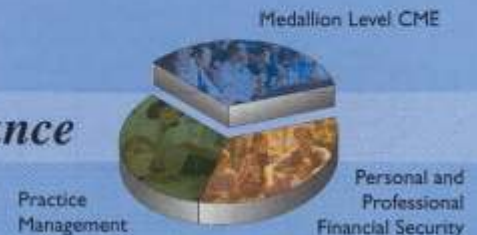
SPECIAL EVENTS

- Nurses' Breakout Session
- National Disaster Medical System,
 Burn Specialty Team-2
- North Carolina Jaycee Burn Center Tour
- Silver Anniversary Banquet

**The Effectiveness Of Silicone
 Thermoplastic Material In The
 Management Of Facial
 Scarring After Burn Injury**

Mary E. Dougherty, PT, and Richard J. Kagan, MD,
 Shriners Hospital for Children, Cincinnati, Ohio

Total Practice Performance



The Effectiveness of Silicone Thermoplastic Material in the Management of Facial Scarring after Burn Injury.¹

Mary E. Dougherty, PT & Richard J. Kagan, MD

SHRINERS BURN HOSPITAL FOR CHILDREN, CINCINNATI, OHIO

Therapists utilize a variety of interventions to manage scarring and improve the function of burn injured patients. The use of pressure appliances is one such intervention. Pressure garments and pressure appliances (such as face masks and neck collars) are used to help the patient achieve a positive cosmetic outcome after skin grafting. This case study demonstrates the burn care team's determination in providing the best appliance for an aesthetic graft.

A 3 year old child was initially fitted with an elastic headband two weeks after split thickness autografting to the forehead (Figure 1). Over a twelve week period, two modifications were made to the headband (Figure 2). First, Velfoam[®] was added to increase the pressure delivered to the area. Second, the width of the headband was increased and the material was changed to a silicone-lined elastic material. After wearing the headband for five months, the child was casted for a partial face mask and fit with the device two weeks later. The Silon-STS[®] forehead mask was secured with 3 straps and a beanie. The family received verbal instruction regarding the wearing schedule, application and care of the device.

The patient was compliant with the wearing schedule and performing massage as instructed. Eleven months after the surgical procedure, the skin graft was mature and the mask was discontinued (Figure 3). Although a formal scar assessment was not performed, the graft was noted to have a favorable appearance – flat, smooth and pliable, albeit hyperpigmented.

This patient had an improved cosmetic outcome after wearing the Silon-STS[®] device. Whether the good outcome was directly related to the type of material used is not known. A prospective study comparing uvex material and Silon-STS[®] would be of great benefit in order to provide patients with the best appliance for a favorable outcome.

¹ [abstract] In: Proceedings of the 19th Annual Southern Region Burn Conference 2006; Nov 3-5 Durham, NC, p.82.

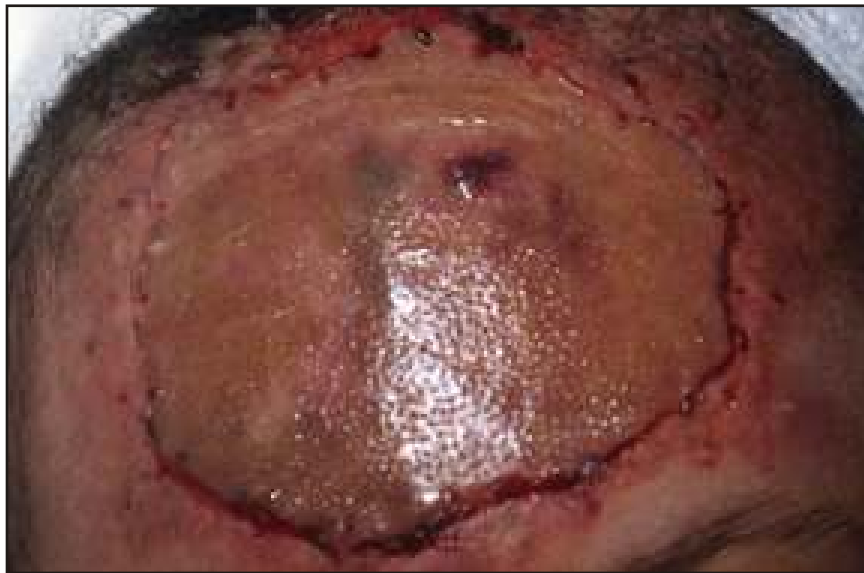

Figure 1: Post operative skin graft at 2 weeks

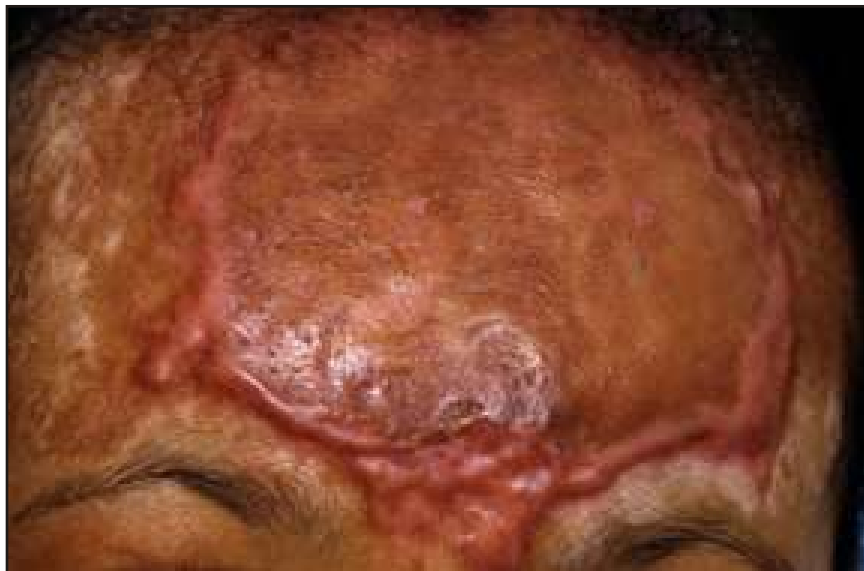

Figure 2: Scar presentation after 5 months of treatment with pressure alone

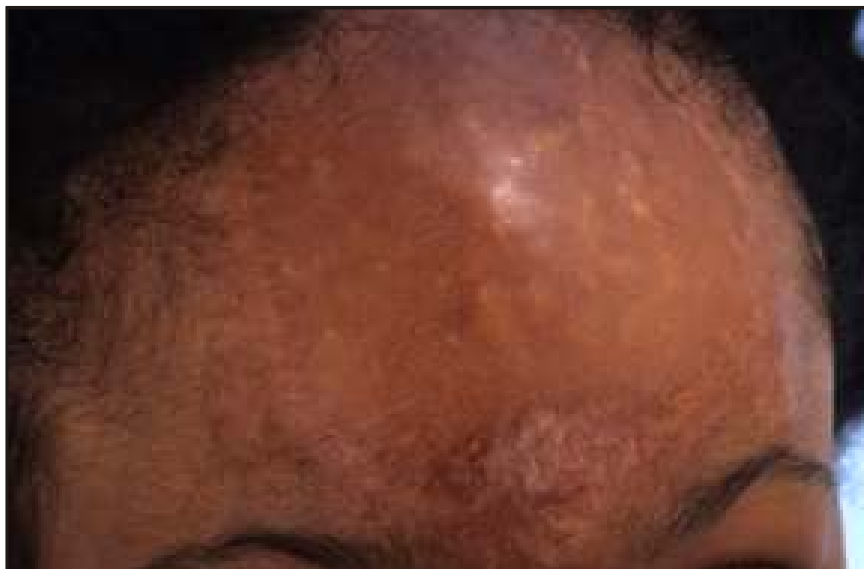

Figure 3: Final scar presentation after treatment with Silon-STS Forehead Mask

