


Cosmetic



Dermatology<sup>®</sup>

October 1995

---

Promising Results Found  
With New  
Interpenetrating Polymer Network

Robert A. Weiss, MD and Margaret A Weiss, MD

---

by Robert A. Weiss, M.D.,  
Margaret A. Weiss, M.D.

## PROMISING RESULTS FOUND WITH NEW INTERPENETRATING POLYMER NETWORK

*A new wound dressing consisting of a thin film of silicone and polytetrafluoroethylene interpenetrating polymer networks has been tested for use following facial resurfacing by dermabrasion. Results of the study are quite promising, leading to additional studies of the dressing's use in laser resurfacing.*

It has been known for well over a decade that abrasion injuries of the epidermis with partial injury of the dermis heal more quickly when kept moist by using occlusive dressings. This fact has led to the use of dressings such as polyethylene oxide gel routinely after dermabrasion. With the addition of laser resurfacing to our practice, it has become clear that this gel dressing is a bit bulky for the relatively short-lived exudate and often smaller areas treated by a flash-scanned laser.

The purpose of our study was to investigate the use of a new wound dressing consisting of silicone and polytetrafluoroethylene interpenetrating polymer networks in a thin film. The film is stretchable and includes small perforations for exudate drainage. Its potential advantages are that it allows rapid application, excellent

reepithelialization and the potential to reduce hypertrophic scarring following wounds such as dermabrasion and laser resurfacing.

### Advantages of the Polymer Network

Silicone with polytetrafluoroethylene interpenetrating polymer network dressing fulfills the requirements for an ideal dressing after epidermal removal (see Figure 1). These include nonadherence to the wound, no tendency to reinjure the wound with removal, the accumulation of growth factors at the wound surface and oxygen exchange. Other properties that facilitate its use are easy application by the medical team and easy removal by the patient at home. The polymer network is lightweight and allows facial movement without much movement of the secured dressing. It can be formed into a face mask that is placed over the entire face and held in place tightly by tying it around the back of the head (see Figure 2). Since it is made of the same material as Silon SES, which is marketed for treatment of hypertrophic scarring, we thought there might be some possibility of obtaining a better long-term cosmetic result with early use of this dressing.

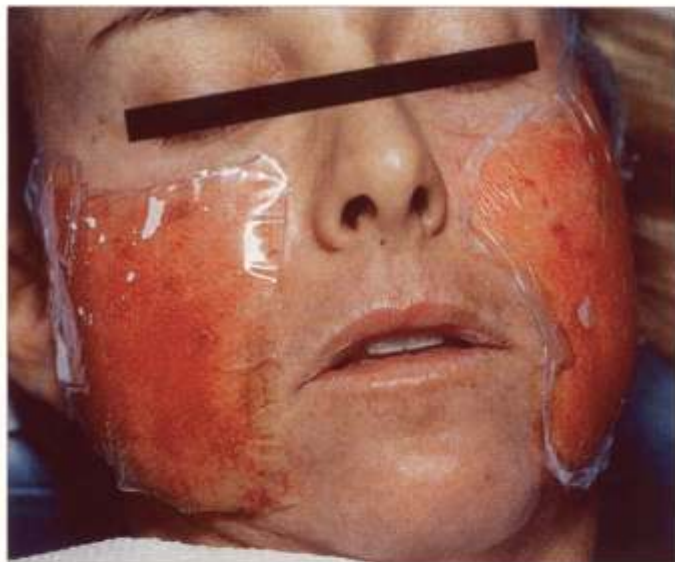

Figure 1: Patient with polymer network dressing after laser resurfacing

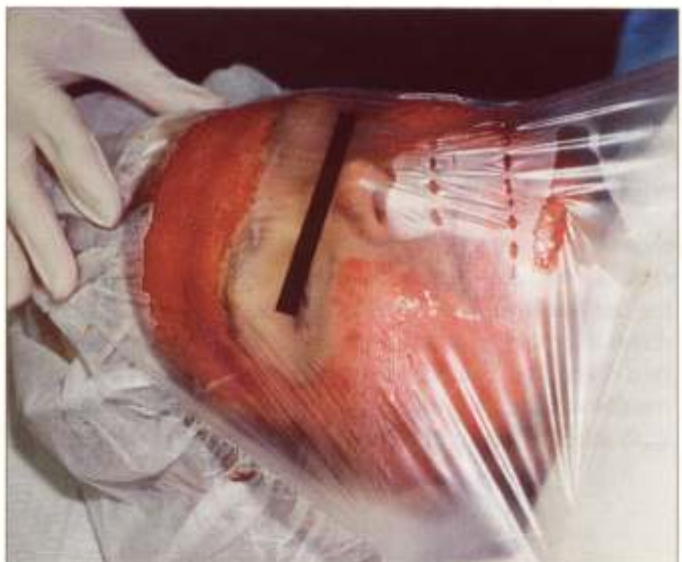

Figure 2: Polymer network dressing being applied as a face mask immediately after dermabrasion

### **A Bilateral Comparison of Wound Dressings**

Our study consisted of a bilateral comparison of a polyethylene oxide gel dressing versus the silicone/polytetrafluoroethylene dressing. Following full face dermabrasion, seven patients had polyethylene oxide gel applied to the right cheek and the silicone and polytetrafluoroethylene polymer applied to the left cheek. Dressings were changed at 24 and 48 hours postsurgery. Healing was evaluated on Days 1, 2 and 3

*The purpose of our study was to investigate the use of a new wound dressing consisting of silicone and polytetrafluoroethylene interpenetrating polymer networks in a thin film.*

and Weeks 1, 2, 4, 8, 12, 16, 20 and 24. Photographs were taken at all phases and used for comparison evaluation.

As compared to polyethylene oxide gel, patients preferred the silicone with polytetrafluoroethylene polymer during early healing, due to increased mobility, less accumulation of exudate at the base of the dressing (with the perforated form of the dressing) and no adherence of residual dressing to the wound base. From our point of view, the ease of application was better since the polymer dressing had less tendency to slide around following application. Our staff preferred to use the silicone with polytetrafluoroethylene dressing and, following the conclusion of the study, we began to use the entire face mask as a rapid means to cover the entire dermabraded face.

Relative lack of postoperative pain and fast rate of short-term healing were essentially equal on both cheeks. We have been using the polyethylene oxide gel for the last 8 years with excellent cosmetic results and did not expect to observe much difference between the two dressings. Surprisingly, patients rated the cosmetic results at 6 months slightly better on the side treated with silicone and polytetrafluoroethylene polymer,

although this was by no means statistically significant. Our impression was that patients were able to resume normal activities such as tooth brushing more quickly

*As compared to polyethylene oxide gel, patients preferred the silicone with polytetrafluoroethylene polymer during early healing.*

with the polymer. Polyethylene oxide gel has been occasionally observed to leave a residue at 48 hours on the wound; this was not observed with silicone with polytetrafluoroethylene dressing.

### **Conclusion and Outlook**

We concluded that the new wound dressing consisting of silicone and polytetrafluoroethylene interpenetrating polymer networks offers an additional way to allow excellent wound healing following dermabrasion. This dressing achieves results comparable to polyethylene oxide gel and offers advantages in many respects. Based on the experience following dermabrasion, we are currently conducting a similar study following laser resurfacing. Preliminary results indicate that the polymer network dressing will be easy to use and will increase patient comfort and may accelerate reepithelialization. We are hopeful that optimal cosmetic results will be achieved with the fastest healing time. ▲

Robert A. Weiss, M.D., and Margaret A. Weiss, M.D., are assistant professors at Johns Hopkins University School of Medicine, Baltimore, Md.

Note: The polytetrafluoroethylene interpenetrating polymer network film used in this study is Silon™ II, manufactured by BioMed Sciences, Inc., Bethlehem, Pa. The authors have no financial interest in Silon II or BioMed Sciences, Inc.